

Late Complications of Laparoscopic Adjustable Gastric Banding (LAGB): Saudi Arabia Experience

ABDULRAHMAN A. ASHY, FRCSI, FICS, AHMED M. KENSARAH, FRCS(Ed)
ABDULRAHMAN M. MECCAWY, FRCS(Ed), RASHAD AL-KASHGARI, FRCS(Glas),
ABDULRAHMAN SIBIANY, FRCS(Ed), and FAISAL AL-MASHAT, FRCS(I)(Ed)
*Department of General Surgery, Faculty of Medicine & Allied Sciences,
King Abdulaziz University, Jeddah, Saudi Arabia*

ABSTRACT. Postoperative complications of laparoscopic adjustable gastric banding (LAGB) are not uncommon as reviewed from the literature. The intra-operative complications such as bleeding, injury to the abdominal organs, or perforation of the stomach during dissection are usually obvious and can be managed immediately, while the late complications are usually discovered during the follow-up visits and need to be corrected soon, e.g., food intolerance, pouch dilatation, and stomach slippage as well as complications of the access port. The present work describes the experience of the team to use the lap band covering a period from October 1995 to October 1997 by which 150 cases were done. Five cases were done using the open method while 145 cases were performed laparoscopically. Only one death had occurred (0.6%) while 14 cases of gastric (stomach) slippage (9.6%) and one case of access port rotation (0.6%) were recorded. The above three complications occurred exclusively in the laparoscopic group. The gastric slippage was successfully corrected laparoscopically and the rotated access port was re-adjusted through a small skin incision under local anaesthesia.

Keywords: Morbid obesity, Laparoscopic adjustable gastric banding, Complications, Pouch dilatation, Stomach slippage.

Introduction

Obesity has always been a problem in all the communities all over the world, including Saudi Arabia^[1]. It is estimated that about 15% of the population are affected^[1] and

Correspondence & reprint requests to: Prof. Abdulrahman A. Ashy, P.O. Box 6615, Jeddah 21452, Saudi Arabia.

Accepted for publication: 8 June 1998. Received: 8 March 1998.

obesity is an underlying factor in many diseases; yet, surprisingly, it has, until recently, attracted little medical or scientific interest. In Great Britain, it is defined as a body mass index (BMI) $>30 \text{ kg/m}^2$ while overweight is considered when the BMI is $>25 \text{ kg/m}^2$. An alternative method of defining obesity is by measuring the waist circumference which is $>80 \text{ cm}$ for women and $>94 \text{ cm}$ for men. Medical or surgical intervention is considered necessary to treat obesity if the waist circumference is $>88 \text{ cm}$ for women or $>102 \text{ cm}$ for men^[2]. Conventional dieting, as well as appetite suppressant drugs, were used to decrease the weight but proved to be intolerable in the long-term or had side effects^[3]. Many types of barbaric surgical procedures were performed since the early 1950s and are still modified every now and then to obtain the most effective procedure with the least side effects^[4]. A study comparing barbaric surgery versus conventional dieting in morbid obesity showed the superiority of the former to the latter^[5]. It is worthwhile to mention that although the surgical procedures performed to decrease body weight of an individual are superior to dieting and the use of pharmaceutical agents, patients are not yet immune from their own side effects. Rapid pulse due to acute gastric dilatation or acute afferent loop syndrome and peritonitis can occur and is considered to be fatal if not recognized and treated before the sun sets or rises^[6]. Complications related to the application of the gastric band around the upper portion of the stomach such as food intolerance, pouch dilatation, and stomach slippage as well as wound infection, band or reservoir (access port) infection, pneumonia, and atelectasis, in addition to splenic injury and band erosion, have also been recorded^[7,8]. In the present paper, our experience in performing LABG on 150 cases is described and discussed in relation to complications of the procedure.

Patients and Methods

Over a period of two years from October 1995 to October 1997, a total of 150 cases of adjustable silicone gastric banding as a restrictive gastric procedure to treat morbid and super-obesity using the lap band Bioenteric™ were performed. The first five cases were performed by the open method to master the technique while the subsequent 145 cases were done laparoscopically. Seventeen (17) cases of dilated pouches and stomach slippages have occurred in the present series. Three were treated successfully by balloon deflation but 14 needed surgery (Fig. 1, plates 1-4). All were in the laparoscopic group. None of the cases done conventionally had the same problem. This was due to better fixation of the posterior gastric wall of the pouches using the sensation of the hands. Twelve out of the 14 patients who had a re-operation were females (85.7%) and two were males (14.3%). Twelve of the 17 stomach slippages occurred in those patients who had their surgery during the first year of the study (70.6%) while five occurred during the second year (29.4%). The time interval between the original operation and the re-do or the re-positioning ranged between 2 to 15 months (mean=6.5 months). All of the re-operated slippages were posterior and none occurred anteriorly^[9]. Six of the slipped stomachs were corrected and repositioned laparoscopically without any difficulties by putting two to three gastrogastic stitches posteriorly through the lesser sac (42.8%) while four cases (28.6%) had to have a re-do operation because of severe fibrosis around the stomach, preventing its reduction through the band. A new

band was applied above the level of the old one after the removal of the latter in the same operation. The other four cases had their bands removed by other surgeons and re-done later by the team on another occasion (28.6%).

The diagnosis of the case of a slipped stomach was based on the patient's symptoms in the form of repeated vomiting and food intolerance and even fluids. Barium x-ray checkup showed rotation of the band and complete obstruction of the gastrogastic stoma with a huge dilatation of the upper pouch (Fig. 2, plate 1). Complete deflation of the balloon reversed the condition in three patients and solved the problem (Fig. 1, plate 6). The patient was then instructed to take small amounts of fluids at a time and to lie on the right hand side to enhance the evacuation of the upper pouch by dependency to prevent recurrence. Review of the patient with another barium x-ray checkup was done after two weeks. In the three cases where the slippage had remained corrected, the patient was advised not to have the balloon of his band inflated anymore unless it became truly necessary. But in those where the slippage appeared to be irreducible, re-operation was deemed necessary (Fig. 2, plate 2). The repositioning operation was successfully performed laparoscopically and never demanded open surgery in all the 14 cases. The operating time was short (45 min) and the operation itself was very easy and safe. After giving the patient general anaesthesia with endotracheal intubation and creation of pneumoperitoneum to a pressure of 14 or 15 mmHg because the patient had already lost weight and became slim, the pars flaccida of the hepatogastric ligament was opened and the lesser sac was entered. The slipped pouch was seen dilated posteriorly and the band was rotated and found below the pouch (Fig.1, plate 8). Reduction of the slipped posterior wall of the stomach was achieved by pulling it gently through the band and 2-3 stitches of a non-absorbable material (silk 2/0) were applied between the two gastric pouches to keep the corrected band in place. There was no need to free the band anteriorly and it was, in fact, left undisturbed. Haemostasis was achieved and no drain was used. The trocars were removed under vision and the wounds were closed after deflation of the CO₂.

In the re-do operation, the above procedure was adopted but because of fear of gastric perforation due to the severe adhesions from the original operation and the fibrotic reaction of some patients towards silicone, the band was freed anteriorly with great care during dissection and then removed. A new band was inserted at a higher level and fixed in place with silk size 2/0 stitches anteriorly and posteriorly when possible or left without the posterior fixation. The stomach will rarely slip again because of its fixation by the surrounding fibrosis and adhesions. There was no need to change the access port in both situations. Patients were discharged home on the first postoperative day and barium x-ray checkup was done one week later to confirm the correction (Fig. 2, plates 2-3)). In the case of the rotated access port, the patient was admitted as a day case where exploration of the port site was done under local anaesthesia and the prosthesis was re-adjusted and fixed to the anterior rectus sheath with silk stitches (size 0).

Results

One hundred and fifty cases of adjustable silicone gastric banding were performed

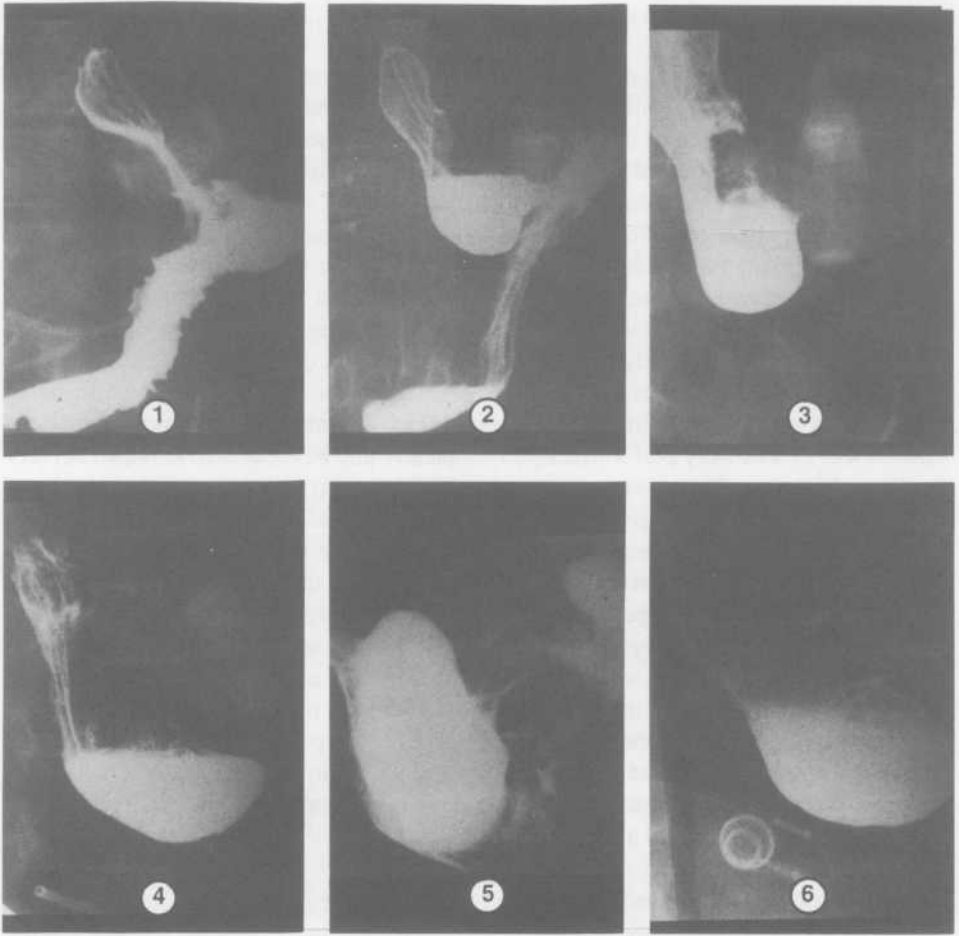


Fig. 1: Plate 1. Barium meal showing normal appearance of the band and pouches. Plate 2. Barium meal showing dilatation of the upper pouch of the stomach without stomach constriction. Plate 3. Barium meal showing dilatation with complete stomach obstruction. Plate 4. Barium meal showing the stomach slippage. Plate 5. Barium meal showing passage of barium through the stoma after complete deflation of the balloon. Plate 6. Barium meal showing irreducible stomach slippage and rotation of the band.

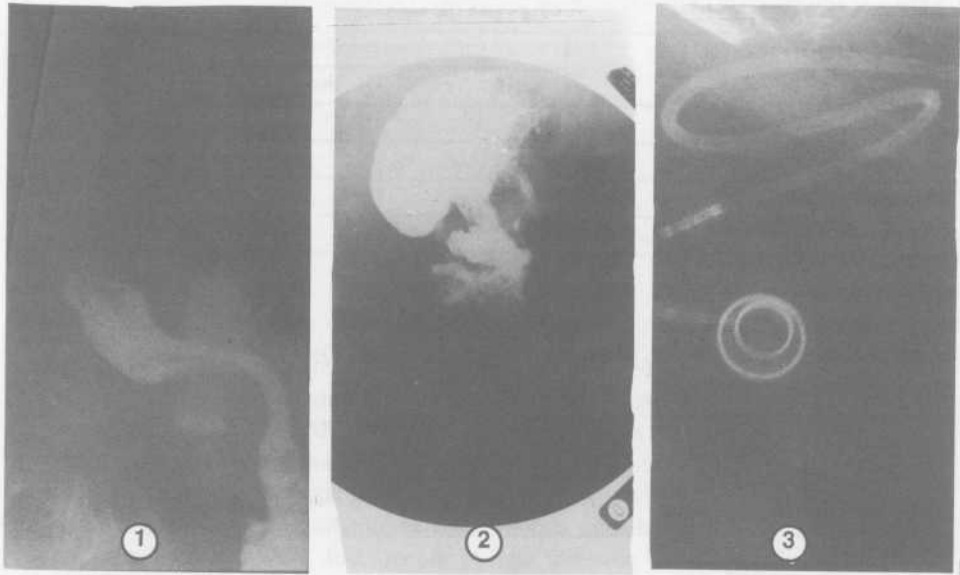


Fig. 2: Plate 1. Barium meal showing the correction of the rotated band and repositioning of the slipped stomach. Plate 2. X-ray showing the rotated access port before correction. Plate 3. X-ray showing the rotated access port after correction.

by the team over a 2-year period. The first five cases were done conventionally whereas the rest were done laparoscopically. No complications occurred in the conventional group and no major complications occurred in the laparoscopic group. Only one death occurred one week postoperatively from unknown massive pulmonary embolism or probably severe myocardial infarction since the patient was brought into the hospital already dead. No autopsy was done due to religious reasons.

Another complication resulted from rotation of the access port which was corrected under local anaesthesia as a day case. The main complication in the present series was slippage of the stomach. All of them occurred in the laparoscopic group: 12 of them during the first year and 5 during the second year of the study (Table 1). Three cases were managed successfully by deflation of the balloon, but 14 cases had to be re-operated upon to correct the error which was achieved successfully through the laparoscope. Six cases out of the 14 had a repositioning and 6 cases had their bands removed and redone again at a later stage. The other 2 cases were removed completely upon the patients' requests. Barium x-ray checkup was performed two weeks postoperatively and showed correction of the rotated band and the return of the upper pouch to near its original small size.

TABLE 1. Distribution of patients according to post-operative complications.

Complication	Patients No		
	First Year	Second Year	Total
Stomach slippage	12	5	17
Access port rotation	1	0	1
Mortality	0	1	1
Total	13	6	19

Discussion

Although LAGB is an effective procedure to lose weight, it showed many complications when it was first started to be used. Many factors play a part in the occurrence of the complications, *i.e.*, the experience of the surgeon who performs the laparoscopic procedure as well as the amount of fat inside the abdomen and the size of the surrounding organs, *i.e.*, the liver and the spleen. The immediate complications include those which usually occur during surgery such as bleeding, injury to the liver, spleen and bowel, or injury to the posterior wall of the stomach during dissection of the retrogastric tunnel. Management of the above complications should be dealt with immediately. The patient might have his/her laparoscopic procedure converted into an open one to repair the gastric perforation or to perform splenectomy.

The late complications of LAGB are food intolerance, pouch dilatation, and stomach slippage in most of the patients, but rotation of the access port or leakage from it or from the tubing or the band itself might occur and needs change of the prosthesis. Infection around the band or the reservoir (access port) as well as the general complications, (*e.g.*, wound infection, pneumonia, atelectasis, or peritonitis) may occur. Pouch dilatation usually occurs because of overeating, forceful vomiting, or taking sparkling drinks. If this happens, deflation of the balloon usually corrects the condition, but stomach slippage, although it is reversible in some cases, might need re-operation in the form of a repositioning or a re-do (Fig. 3). Band erosion into the stomach wall was reported and needs revision surgery to remove it. No report is found in the literature regarding migration of the band upwards into the posterior mediastinum as it happens with the angel-chick prosthesis^[10].

The mortality rate after this operation is very low. It is usually due to a concomitant disease but can happen after a missed perforation of the stomach or acute gastric dilatation^[6]. It accounts for 0.6% in the present series.

Rotation of the access port is due to an early muscular exercise which might cut the stitches anchoring the access port to the anterior rectus sheath or due to the use of absorbable suture materials to fix it. Pouch dilatation and stoma slippage can be prevented by fashioning a small upper pouch (15 ml or less) and application of more gastrogastric stitches with deflation of the band at the operation and avoidance of over-dissection. The patient should also be instructed to avoid sparkling drinks and over eat-

ing as well as forceful vomiting. If dilatation and slippage occur, conservative management might solve the problem in some cases or else, repositioning or redo operations become mandatory.

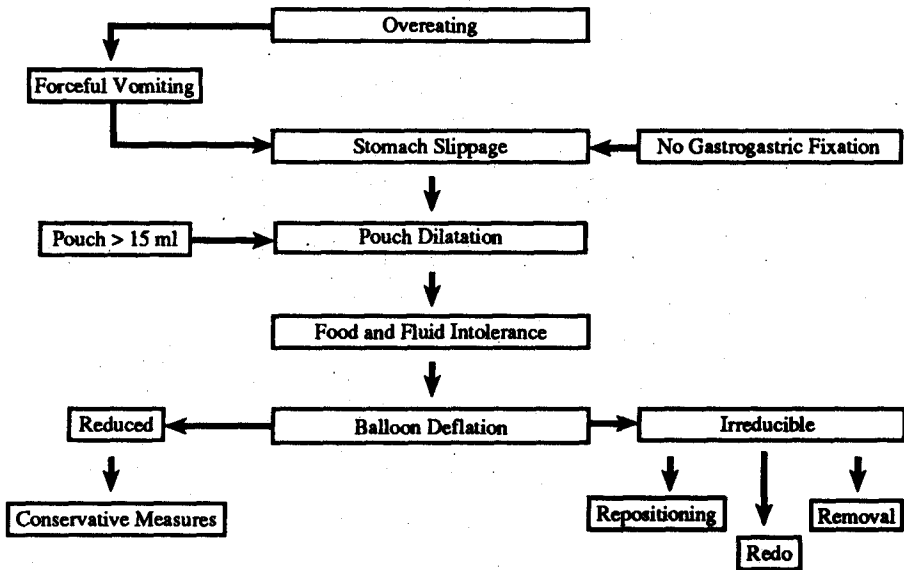


Fig 3. Suggested mechanism of production of pouch dilation and stomach slippage.

In conclusion, pouch dilation and stomach slippage after LAGB are not uncommon late complications of the procedure. Their management depend on the size of the enlarged pouch and the degree of the stenosis of the stoma. Conservative management by deflating the balloon of the band is usually the first step which, if it fails, then a reoperation in the form of a repositioning or a re-do is mandatory to correct the error. It is a safe procedure and proved successful in the present series of 14 cases out of 145 operations of LAGB during a period of two years. Correction of a rotated access port (reservoir) is very simple and is usually done under local anaesthesia as a day case. All of our patients made an uneventful recovery after the correction. To avoid pouch dilatation and stomach slippage, we recommend the following: 1) The pouch size should be small (15 ml or less), 2) Insertion of anterior and posterior gastrogastric stitches, 3) Deflation of the balloon during surgery and after calibrating the stoma, 4) Avoid sparkling drinks and overeating, 5) Avoid forceful vomiting, 6) Liquid diet for 2-3 months postoperatively, 7) Regular follow-up, stoma calibration, and adjustment according to the barium check-up.

Acknowledgment

We would like to thank Elvira D. Malabanan and Russini D. Reyes for their great help in arranging and typing the original manuscript.

References

- [1] Al-Nuaim AR, Al-Rubeaan K, Al-Mazrou Y, Al-Attas O, Al-Daghari N, Khoja T. High prevalence of overweight and obesity in Saudi Arabia. *Int Obes* 1996; 20: 547-552.
- [2] Wilding J. Science, medicine, and the future: obesity treatment. *BMJ* 1997; 315: 997-1000.
- [3] Abenhalm I, Moride Y, Brenot F, Rich S, Benichou J, Kurz X, Higenbottam T, Oakley C, Wouters E, Aubier M, Simonneau G, Begaud B. Appetite-suppressant drugs and the risk of primary pulmonary hypertension. *N Eng Med* 1996; 235: 609-616.
- [4] Ashy AA, Gareer WY, Omayer MS, Meccawy AA. Laparoscopic adjustable silicone gastric banding in the treatment of super obesity in Saudi Arabia. *Int Surg* 1996; 81: 289-291.
- [5] Greenstein RJ, Rabner JG, Taler Y. Bariatric surgery vs conventional dieting in the morbidly obese. *Obes Surg* 1994; 4: 16-23.
- [6] Mason EE. Diagnosis and treatment of rapid pulse. *NBSR Newsletter* 1995; 10(1).
- [7] Lise M, Favetti F, Belluco C, Segato G, DeMarchi F, Foletto M, Enzi G, Busetto L. Stoma adjustable silicone gastric banding: results in 111 consecutive patients. *Obes Surg* 1994; 4: 274-278.
- [8] Kuzmak LI, Burak E. Pouch enlargement: myth or reality? Impressions from serial upper gastrointestinal series in silicone gastric banding patients. *Obes Surg* 1993; 3: 57-62.
- [9] O'Brien P, McMurrick P. Posterior gastric wall prolapse after lap band placement. *Obes Surg* 1995; 5: 247.
- [10] Neltzel S, Kauffman CA. Fever of unknown origin after angelchick anti-reflux prosthesis. *Clin Infect Dis* 1992; 15(3): 528-529.

المضاعفات المتأخرة الناتجة عن عمليات تحزيم المعدة: الخبرة السعودية

مبدالرحمن أشي، أحمد كنسارة، مبدالرحمن مكاري،
رشاد القشقرى، مبدالرحمن صبياني ، وفيصل المشاط
قسم الجراحة العامة، كلية الطب والعلوم الطبية،
جدة، المملكة العربية السعودية

المستخلص. ان مضاعفات حزام المعدة لعلاج السمنة المفرطة ليس هو بالشيء النادر حسب مراجعتنا لما نشر في هذا المجال. فهناك من المضاعفات ما يحدث أثناء العملية مثل النزيف أو جرح الكبد أو الطحال وهذه من الممكن مشاهدتها وبالتالي علاجها أثناء العملية نفسها. ولكن هناك مضاعفات أخرى لا تظهر على المريض الا بعد مضي زمن ما بعد العملية مثل عدم القدرة على تناول الطعام أو الشراب بسهولة أو توسع حجم المعدة الصغير أو انزلاق المعدة أو انقلاب خزان التحكم، وهذه المضاعفات يجب علاجها في اقرب فرصة بعد اكتشافها. لقد بدأنا إجراء هذه العملية في أكتوبر ١٩٩٥م وأجرينا منها ١٥٠ عملية حتى أكتوبر ١٩٩٧م، خمسة منها عن طريق فتح البطن ومائة وخمسة وأربعون عن طريق المنظار الجراحي. لقد حدثت حالة وفاة واحدة فقط بسبب جلطة في القلب بعد العملية بإسبوع (٦٪) كما حدث انزلاق للمعدة لدى مريض (٩,٦٪) وحالة واحدة لانقلاب خزان التحكم (٦٪) ولم تحدث أية مضاعفات أخرى. لقد حدثت تلك المضاعفات الثلاث المذكورة أعلاه في المرضى الذين أجريت لهم عملية تحزيم المعدة باستخدام المنظار الجراحي، وقد تم تعديل المعدة المنزلة إلى وضعها الطبيعي باستخدام المنظار الجراحي أيضاً دون حاجة لفتح البطن، كما تم تعديل الخزان المقلوب عن طريق فتحة في الجلد فوق الخزان وتحت تأثير المخدر الموضعي.

