

# Outcome of bilateral periventricular nodular heterotopia in monozygotic twins with megalencephaly

Mohammed M S Jan\* MBChB FRCP(C), Department of Paediatrics (Neurology), King Abdulaziz University Hospital, PO Box 6615, Jeddah 21452, Kingdom of Saudi Arabia.

\*Correspondence to author at above address.

**Bilateral periventricular nodular heterotopia (BPNH) is a neuronal migration disorder, characterized by grey-matter cellular rests in the periventricular regions. Patients frequently present with seizures during childhood or later in life. Monozygotic twin sisters were found to have enlarged head circumferences (>95th centile) during a routine medical visit at 6 months of age. A brain CT scan revealed grey-matter cellular rests in the subependymal regions extending to the subcortical white matter. In some areas these cell aggregates had nodular margins, consistent with the diagnosis of BPNH. At 6 years of age they are cognitively and neurologically normal. They have not had any seizures and their heads continue to grow along the 95th centile.**

Neuronal heterotopias are a form of disordered neuronal migration (Volpe 1995). They represent collections of neurones in the subcortical white matter, apparently arrested during radial migration (Volpe 1995). There are three types of neuronal heterotopias: subependymal, cerebral white matter, and superficial cortical-leptomeningeal (Barths 1987, Hirano et al. 1992, Volpe 1995). The cerebral white-matter heterotopias can be focal, bilateral (diffuse) nodular, or diffuse laminar (band heterotopias) in distribution (Barkovich et al. 1989). Seizures are present in all three types of heterotopias (Smith et al. 1988, Barkovich and Kjos 1992, Huttenlocher et al. 1994). These children frequently have abnormalities of motor function and cognitive development, particularly those with band heterotopias who have had the most consistently unfavourable neurological outcome (Barkovich and Kjos 1992).

Patients with bilateral periventricular nodular heterotopia (BPNH) have a relatively mild phenotype, with normal intelligence and frequent seizures (Dobyns et al. 1996). The age of onset of seizures varied between 4 and 25 years in one series (Huttenlocher et al. 1994). Megalencephaly was never noted in the affected children. In one of the documented patients with BPNH, the head circumference at 2 years of age was at the 25th centile (Huttenlocher et al. 1994). Preliminary linkage analysis in several of the multiplex families showed a localization of the gene to distal Xq28 (Eksioglu et al. 1996). This paper describes monozygotic twin sisters with BPNH who initially presented with an enlarged head circumference and no neurological or cognitive dysfunction.

## Case report

White monozygotic twin sisters from Nova Scotia, Canada were born at 39 weeks of gestation after an uneventful pregnancy. The gravida 4 para 2 mother was aged 29 years. Delivery was spontaneous and uncomplicated. Both girls were well at birth and required no resuscitation. A 7-year-old sister and a 9-year-old brother are both healthy.

At the age of 6 months the twins' head circumferences

were noted to be enlarged above the 95th centile (weight was at the 25 to 50th centile and height at 50 to 75th centile). Cranial ultrasound revealed no hydrocephalus. A brain CT scan at 11 months of age revealed similar findings in the two subjects (Figs 1 and 2): grey-matter cellular rests in the subependymal regions extending to the subcortical white matter, and in some areas these cell aggregates had nodular margins, consistent with the diagnosis of BPNH.

The sisters continued to develop normally with a remarkable similarity. They rolled over at 4 to 5 months, crawled at 9 to 10 months, stood unsupported at 12 months, and walked by 15 months. Neurological assessment at 16 months was normal. At 20 months of age they spoke at least 10 words, were able to use a spoon, and continued to show normal motor development. Repeat examination by a paediatric neurologist was normal at 3.5 years of age. Their head circumferences were growing along the 95th centile. At 6 years of age they have no evidence of cognitive or motor deficits. Their language development continues to be age appropriate and they remain seizure free. The normal development was confirmed using the Child Development Inventory questionnaires (Irton 1992).

### Discussion

Several studies have shown a consistently unfavourable neurological outcome of band heterotopias (Smith et al. 1988, Barkovich and Kjos 1992, Huttenlocher et al. 1994). Bilateral periventricular nodular heterotopia, on the other hand, gen-

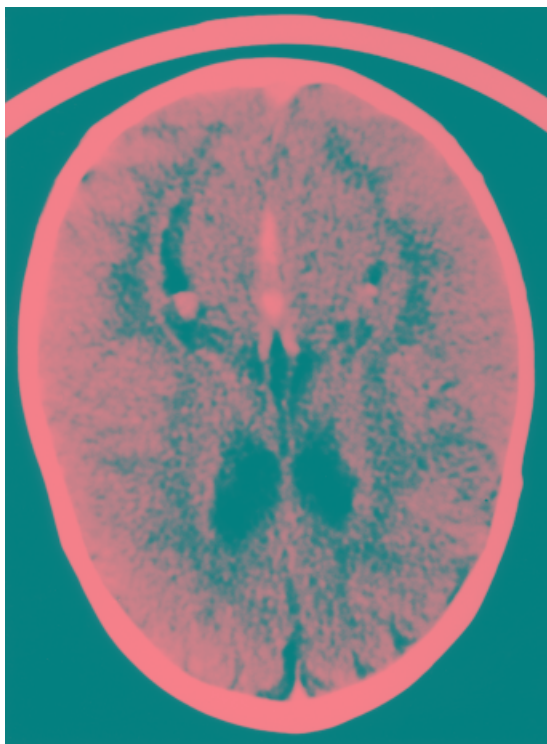
erally has a more favourable outcome (Dobyns et al. 1996). In 1992, Barkovich and Kjos correlated the neuroimaging findings with developmental and neurological manifestations in 20 patients. They found that children with band heterotopias had the most consistently unfavourable neurological outcome. This was in the form of seizures, abnormal motor function, cognition, or speech development. Children with pure periventricular heterotopias ( $N=8$ ) frequently had seizures but abnormalities of motor function and cognitive development were unusual.

In 1994, Huttenlocher et al. studied a large family in which six members in four generations had periventricular nodular heterotopias. Epilepsy was found to be the major clinical manifestation of this developmental defect. Their findings indicated that this developmental defect may be genetically determined. This was later confirmed, and the disorder has been mapped to chromosome Xq28 (Eksioglu et al. 1996).

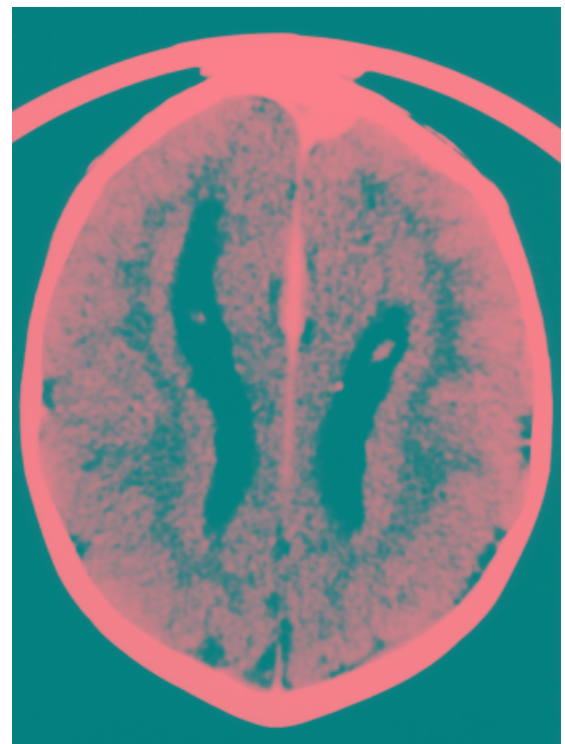
Apart from megalencephaly, our two patients had a completely asymptomatic clinical course. This presentation has not been observed in the previously published cases. To our knowledge BPNH has not been reported in the English literature in either monozygotic or dizygotic twins.

### Conclusions

Bilateral periventricular nodular heterotopia may present in early childhood with an enlarged head circumference. The neurological and cognitive functions may remain normal



**Figure 1:** CT scan of the first twin showing the nodular grey-matter cellular rests in the subependymal regions extending to the subcortical white matter.



**Figure 2:** CT scan of the second twin showing similar nodular grey-matter cellular rests in the subependymal regions extending to the subcortical white matter. Note that the CT cut is not at the same level of that of twin 1 (Fig. 1).

despite the presence of this diffuse developmental disorder. There is a remarkable variability in the spectrum and onset of neurological impairment in this disorder. Recognition of this feature is useful in counselling children with this disorder and their parents.

Accepted for publication 18th February 1999.

#### Acknowledgements

I wish to thank Dr Kevin Gordon (Halifax, NS, Canada) for giving me the opportunity to write up these cases, for his comments during preparation of the article, and for critically reviewing the initial manuscript.

#### References

- Barkovich AJ, Jackson DE, Boyer RS. (1989) Band heterotopias: a newly recognized neuronal migration anomaly. *Radiology* **171**: 455–8.
- Kjos BO. (1992) Grey matter heterotopias: MR characteristics and correlation with developmental and neurologic manifestations. *Radiology* **182**: 493–9.
- Barths PG. (1987) Disorders of neuronal migration. *Canadian Journal of Neurological Sciences* **14**: 1–16.
- Dobyns WB, Andermann E, Andermann F, Czapansky-Beilman D, Dubeau F, Dulac O, Guerrini R, Hirsch B, Ledbetter DH, Lee NS, et al. (1996) X-linked malformations of neuronal migration. *Neurology* **47**: 331–9.
- Eksioglu YZ, Scheffer IE, Cardenas P, Knoll J, DiMario F, Ramsby G, Berg M, Kamuro K, Berkovic SF, Duyk GM, et al. (1996) Periventricular heterotopia: an X-linked dominant epilepsy locus causing aberrant cerebral cortex development. *Neuron* **16**: 77–87.
- Hirano S, Houdou S, Hasegawa M, Kamei A, Takashima S. (1992) Clinicopathologic studies on leptomeningeal glioneuronal heterotopias in congenital anomalies. *Pediatric Neurology* **8**: 441–4.
- Huttenlocher PR, Taravath S, Mojtahedi S. (1994) Periventricular heterotopia and epilepsy. *Neurology* **44**: 51–5.
- Irton H, editor. (1992) *Child Development Inventory*. Minneapolis, MN: Behavioral Science Systems.
- Smith AS, Weinstein MA, Quencer RM, Muroff LR, Stonesifer KJ, Chaney Li F, Wener L, Soloman MA, Cruse RP, Rosenberg LH, et al. (1988) Association of heterotopic grey matter with seizures: MR imaging. *Radiology* **168**: 195–8.
- Volpe JJ. (1995) Neuronal proliferation, migration, organization, and myelination. In: Volpe JJ, editor. *Neurology of the Newborn*. 3rd edn. Philadelphia: WB Saunders. p 43–92.

## Notice

### 7th World Congress of the World Association for Infant Mental Health (WAIMH)

Montréal, Québec, Canada. July 26–30, 2000

The topic of the congress is Diversity: Challenges and Opportunities in Infancy. The theme will be discussed within the context of brain behaviour, developmental psychopathology, culture, environmental health, caregiving, and special babies/special caregivers. This Congress is relevant to all individuals working with preschool children and their families. For further information please contact: WAIMH/Secretariat, 550 Sherbrooke Street West, West Tower, Suite 490, Montréal, Québec, Canada H3A 1B9. Tel: +514 398 3770; Fax +514 398 4854. E-mail: waimh@ums1.lan.mcgill.ca Website: <http://www.mcgill.ca/mco.waimh>